

Case Report

An unusual case of aorta–right atrial tunnel with windsock aneurysm: imaging, diagnosis and treatment

Shehzaadi Aneesah Mohamed Khan, Leonie Scholtz, F Adriaan Snyders, Johan de Villiers

Abstract

The first successfully diagnosed and treated case of aorta–right atrial tunnel was reported by Coto *et al.* in 1980. The most common cause of aorta–right atrial tunnel is a ruptured aneurysm of the sinus of Valsalva. Sinus of Valsalva aneurysms had been reported as early as 1840 by Thurnam; these were diagnosed at autopsy. With the advances in radiology, many cases of aorta–right atrial tunnel have been reported since then, each with its own subtle variations.

We report on a unique case of aorta–right atrial tunnel with a windsock aneurysm in the right atrium. A 55-year-old male presented with abdominal pain and the chest X-ray revealed cardiomegaly. On further investigation with echocardiography and computed tomography angiography, there was an incidental aorta–right atrial tunnel with a windsock aneurysm in the right atrium. He was treated successfully with surgery. A similar case has been reported only once before by Iyisoy *et al.* in 2014.

Keywords: aorta–right atrial tunnel, aneurysms of the sinus of Valsalva

Submitted 27/10/15, accepted 10/7/16

Published online 15/3/17

Cardiovasc J Afr 2017; 28: e1–e5

www.cvja.co.za

DOI: 10.5830/CVJA-2016-073

As early as 1840, aneurysms of the sinus of Valsalva were described by Thurnam; these were diagnosed through autopsies.¹ The first successfully diagnosed and treated case of aorta–right atrial tunnel was reported by Coto *et al.* in 1980.² Initially, diagnosis was limited to echocardiography and cardiac catheterisation, but with the advent of 64-slice computed tomography (CT) angiography, diagnostic accuracy and accessibility has improved. We present here a unique case of aorta–right atrial tunnel with a windsock aneurysm in the right atrium, diagnosed with echocardiography and CT angiography and successfully treated with surgery.

University of Pretoria, Pretoria, South Africa

Shehzaadi Aneesah Mohamed Khan, MB ChB,

aneesahkhan@hotmail.com

Leonie Scholtz, MB ChB, MMed (RadD)

F Adriaan Snyders, MB ChB, MMed (Int), FACC, FESC

Johan de Villiers, MB ChB, MMed (thorax), GKC (thorax)

Case report

A 55-year-old male patient presented with abdominal pain and was admitted to hospital for the treatment of a kidney stone. Two days after the stone was removed and a stent was placed, he complained again of severe abdominal pain, nausea and vomiting. He was thoroughly examined; the abdominal CT and ultrasound were normal. The cause of abdominal pain was due to a urinary tract infection, which he had contracted after the urinary tract stone was removed. The abdominal symptoms were unrelated to the cardiac findings. The chest radiograph, however, demonstrated cardiomegaly. He was then referred to a cardiologist.

The patient had no history of cardiac disease and reported no chest pain or palpitations. He had normal effort tolerance. In retrospect he recalled some ankle swelling during the afternoons and mild peri-orbital swelling during the mornings. His surgical history included a Nissen fundoplication.

A transthoracic echocardiogram demonstrated a large left atrium and left ventricle. No left ventricular hypertrophy was reported. Ejection fraction on M-mode was normal. A significant finding was an impression on the enlarged right atrium from a possible adjacent lesion.

The transoesophageal echocardiogram (TEE) confirmed normal valvular and left ventricular function. There was an aneurysm of the aortic sinus with a windsock in the right atrium, possibly increasing the pressure and volume in the right atrium (Figs 1–3).

A CT angiogram was performed subsequent to the TEE. There was aneurysmal dilatation of the right coronary sinus with a tortuous dilated tunnel draining anteriorly into the right atrium. The distal end of the tunnel appeared to have a large sac/windsock aneurysm, which protruded into the right atrium. The sac was not intact along its lateral border, forming a left-to-right shunt from the coronary sinus to the right atrium. There were extensive calcifications noted along the wall of the tunnel. The right coronary artery arose from the proximal part of the tunnel (Figs 4, 5).

The patient was referred to the cardiothoracic surgeon for surgical repair of the aorta–right atrial tunnel, which was an incidental finding. The defect in the aorta was in the right coronary sinus and the lower border was approximately 4 mm from the aortic annulus (Fig. 6). The aneurysm formed a windsock with more than one opening, all of which were in the right atrium.

The right atrium was opened and a retrograde cardioplegic cannula was placed in the coronary sinus. Retrograde cardioplegia was used due to the presence of the left-to-right shunt created by

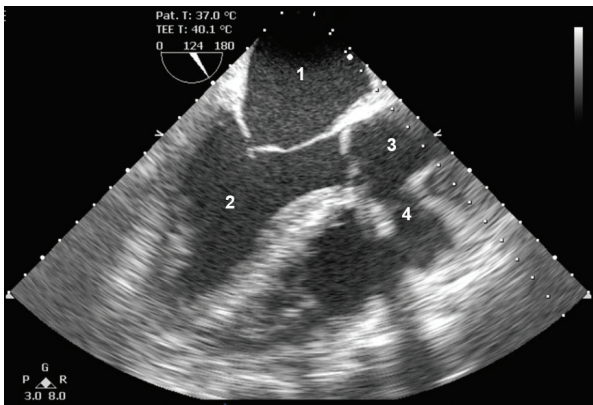


Fig. 1. Two-dimensional transoesophageal echocardiogram in long-axis view. 1, left atrium; 2, left ventricle; 3, aorta; 4, origin of tunnel. The origin of the tunnel arises from the proximal ascending aorta.

the aorta–right atrial tunnel. Anterograde cardioplegia was a less viable option while the shunt between the left and right side of the heart was still patent. The tunnel was approached and excised from both ends (Fig. 7), and it was closed directly with bovine pericardium and prolene sutures at the proximal aorta and right atrium. The aortic annulus was not damaged during the surgery and no valvuloplasty was necessary.

There was a large saccular aneurysm in the right atrium. This was excised and the opening of the windsock was closed directly with sutures. There was no ventricular septal defect. The right coronary artery arose from the tunnel and had atherosclerosis around its origin, and when opened, the middle portion was also atherosclerotic. The right saphena magna vein was harvested for the bypass of the right coronary artery. It was not possible to re-implant the native right coronary ostium as it was too far removed from the ascending aorta. Therefore a distal end-to-side anastomosis was created between the graft and the right coronary artery.

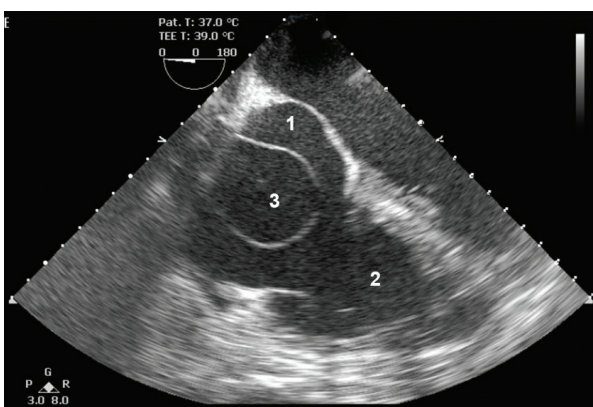


Fig. 2. Two-dimensional transoesophageal echocardiogram in short-axis view. 1, right atrium; 2, right ventricle; 3, aneurysmal sac. The windsock arises from the terminal part of the tunnel and is demonstrated within the right atrium.

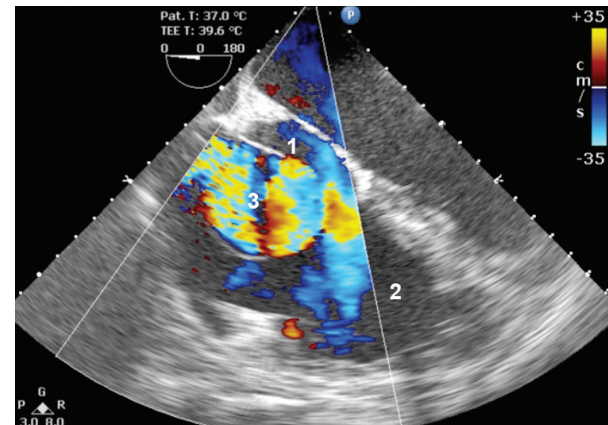


Fig. 3. Two-dimensional transoesophageal echocardiogram with Doppler in short-axis view. 1, right atrium; 2, right ventricle; 3, aneurysmal sac. Turbulent flow is demonstrated within the aneurysmal sac, which empties into the right atrium through a defect in the wall of the sac, thus creating the left-to-right shunt.

The patient followed up with the cardiologist four weeks after surgery. All had gone well, and he reported no dizziness or dysrhythmia. The transthoracic echocardiogram was normal.

Discussion

Aorta–right atrial tunnel is an abnormal extra-cardiac vascular tunnel between any of the aortic sinuses and the right atrium.³ The differential diagnosis includes ruptured aneurysm of the sinus of Valsalva, coronary arteriovenous fistula, rupture of a dissecting aneurysm of the ascending aorta into the right atrium, and pseudo-aneurysm of the right coronary artery followed by

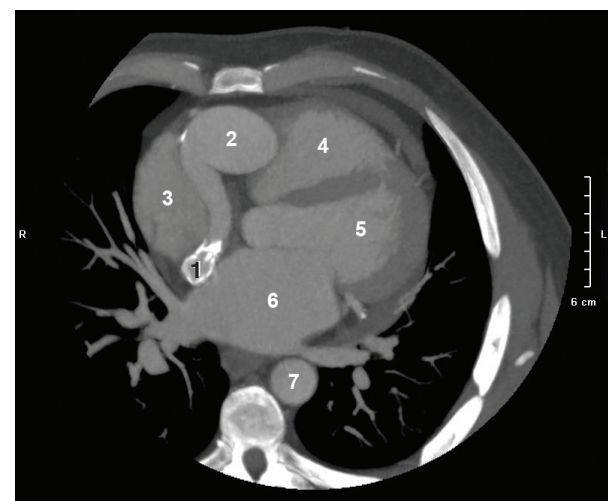


Fig. 4. CT angiogram axial image at the level of the left atrium. 1, distal end of the tunnel; 2, proximal end of the tunnel; 3, right atrium; 4, right ventricle; 5, left ventricle; 6, left atrium. The tunnel is tortuous and dilated. Distally there are mural calcifications in the tunnel.

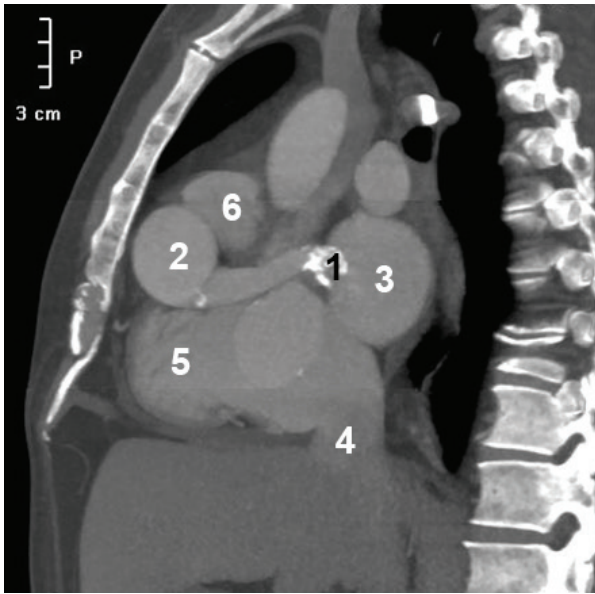


Fig. 5. CT angiogram oblique sagittal image. 1, distal end of tunnel; 2, proximal end of tunnel; 3, left atrium; 4, inferior vena cava; 5, right ventricle; 6, pulmonary trunk; 7, descending aorta. There is a small dense calcification at the origin of the tunnel and dense mural calcifications at the distal end of the tunnel. The tunnel is long, tortuous and dilated.

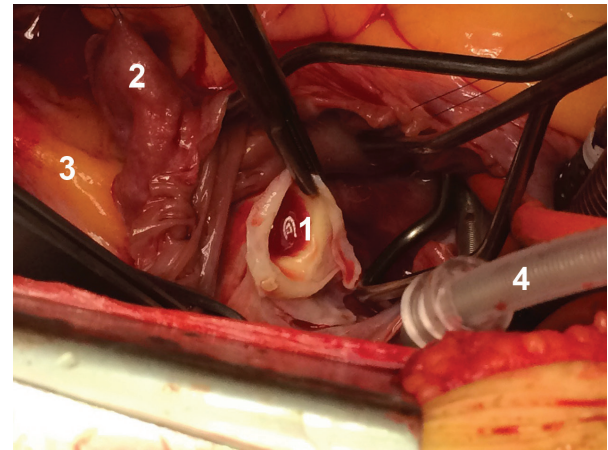


Fig. 7. Intra-operative image. Right atrium is opened and the windssock excised. The distal end of the tunnel is demonstrated opening into the right atrium with a thick collagenised wall due to the high pressure of the shunt. 1, distal end of the tunnel, the opening is within the right atrium; 2, right atrial appendage, which has been retracted; 3, superior vena cava; 4, retrograde cardioplegia cannula.

formation of a fistula between the aneurysm and right atrium.² A ruptured sinus of Valsalva aneurysm is by far the most common cause of aorta–right atrial tunnel.³

Aneurysms of the sinus of Valsalva were first described by Thurman in 1840 and remain relatively rare.¹ The incidence of aneurysm of the sinus of Valsalva is reported to range between 0.1 and 3.5% of all congenital cardiac anomalies. Acquired

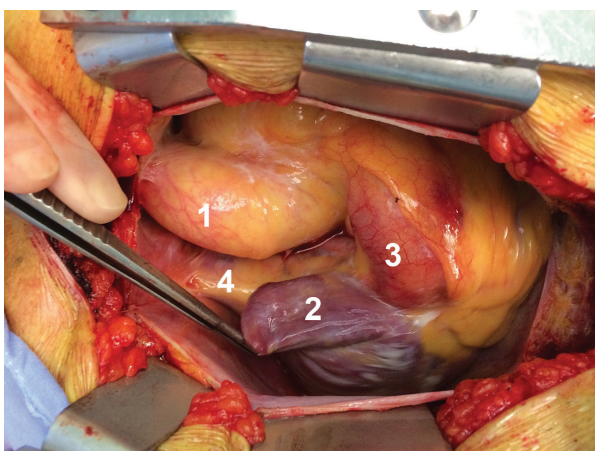


Fig. 6. Intra-operative image. The right atrial appendage has been retracted and the tunnel is demonstrated originating from the proximal aorta. 1, aorta; 2, right atrial appendage; 3, tunnel; 4, superior vena cava.

sinus of Valsalva aneurysms occur less frequently and causative factors include degenerative diseases (atherosclerosis, connective tissue disorders and cystic media necrosis), infections (syphilis, bacterial or fungal endocarditis and tuberculosis), or thoracic trauma.⁴

The aetiopathogenesis of congenital aneurysms is poorly understood.⁵ The right coronary sinus and the non-coronary sinus arise embryologically from the fusion of the bulbar septum and truncal ridges. Incomplete fusion can result in aneurysm formation within the septum when subjected to long-standing systemic arterial pressure (left-to-right shunt).⁶ Weakening of the aortic wall leads to rupture and the establishment of a fistulous tract that may communicate with any of the cardiac chambers, the right atrium being the most common.³ This is also closely related to membranous ventricular septum. Ventricular septal defects occur simultaneously in approximately 40% of patients with congenital aneurysms.⁴

The frequency of ruptured sinus of Valsalva aneurysm varies according to the location: 60% in the right sinus, 42% in the non-coronary sinus and only 10% in the left sinus.⁷

Aorta–right atrial tunnel can be classified according to the origin and course in relation to the ascending aorta, therefore termed anterior or posterior.⁸ Sakakibara and Konno¹⁰ proposed

Table 1. Classification for SVA proposed by Sakakibara and Konno⁹

Type I	Connect the right SV and the existing tract of the RV below the pulmonary valve
Type II	Connect the right SV and the VD in the supra ventricular crest
Type IIIa	Connect the right SV and the RA
Type IIIv	Connect the posterior zone of the right SV and the RV
Type IIIa + v	Connect the right SV and both the RA and RV
Type IV	Connect the non-coronary SV and the RA

SVA, sinus of Valsalva aneurysm; SV, sinus of Valsalva; RV, right ventricle; RA, right atrium.

a formal classification for sinus of Valsalva aneurysm, according to the coronary sinus affected and the area towards which they protrude or rupture (Table 1).

A true aortico-cameral connection may be difficult to differentiate from a coronary cameral fistula. Levy stresses the origin of the abnormal tunnel above and separate from the coronary orifice.¹⁰ Bove and Schwartz, however, emphasise the separation of the orifice of the tunnel from the adjacent sinus of Valsalva by a small well-defined fibrous ridge.¹¹ In our case, the tunnel gave rise to the right main coronary artery.

To date, spontaneous closure of the aorta–right atrial tunnel has not been reported. The pressure that is created during a left-to-right shunt is too high to close spontaneously. Clinical presentation varies according to the degree of the left-to-right shunt, which can range from completely asymptomatic to symptoms related to the volume overload on the ventricles.

Surgical and percutaneous interventions are the main therapeutic options. Transcatheter closure of a tunnel is technically straightforward in the hands of an experienced interventionist. It is cost intensive, but has low peri-procedural risk.¹² Percutaneous intervention with a plug or coil is easiest when the coronary arteries arise separately from the tunnel.

Complications of prolonged patency of the tunnel include calcification of its wall, biventricular volume overload or aneurysmal expansion, congestive cardiac failure, pulmonary vascular disease, infective endocarditis, and higher mortality rate during surgery if the lesion is left uncorrected until the patient ages.¹³ With regard to our patient, the CT angiogram demonstrated calcifications within the wall of the tunnel already.

Multiple aortico-cameral tunnels have been reported once previously in an elderly male patient. Transthoracic echocardiogram, transoesophageal echocardiogram and cardiac catheterisation revealed separate tunnels from the right coronary sinus to the left ventricle, right ventricle and right atrium. Surgery was performed successfully.¹⁴ Mahesh *et al.* presented a case of pre-natal diagnosis of aorta–right atrial tunnel, subsequently treated with percutaneous coil embolisation.¹⁵

Diagnosis

Thurnam diagnosed all ruptured sinus of Valsalva aneurysms at autopsy.¹ In 1951, Venning was possibly the first to diagnose an acute rupture of an aneurysm of the sinus of Valsalva in life.¹⁶ The first successfully diagnosed and treated case of aorta–right atrial tunnel was reported by Coto *et al.* in 1980.²

Aneurysm of the sinus of Valsalva may be difficult to diagnose clinically, and echocardiography is usually the first step to diagnosis.¹⁷ Two-dimensional echocardiography has been improved with the use of contrast, spectral Doppler and colour-flow imaging.⁴ It is non-invasive and easily accessible. Chaing and co-workers were able to accurately diagnose a ruptured sinus of Valsalva aneurysm in 58% of patients using two-dimensional echocardiography alone. The addition of intravenously injected bubble contrast improved the sensitivity to 75%.

One limitation of echocardiography is the inability to visualise the coronary anatomy.⁴ Transoesophageal echocardiography is more sensitive than transthoracic echocardiography due to the probe's proximity to the relevant structures and it optimises echographic windows with distorted anatomy.¹⁸

Ultrasound has improved markedly in the past 15 to 20 years. Three-dimensional echocardiography offers the ability to improve and expand the diagnostic capabilities of cardiac ultrasound. Serial two-dimensional images are obtained and three-dimensional data are reconstructed from this data set, thereby complimenting and supplementing two-dimensional cardiac imaging. Thus far it has been successfully applied to the detection and assessment of several anatomical cardiac defects. This method has not yet been specifically applied to the detection or imaging of aorta–right atrial tunnel. Further technological improvements and additional clinical studies will broaden the list of appropriate applications of this exciting new ultrasound modality.¹⁹

Cardiac catheterisation and retrograde angiography have been considered necessary to differentiate these aneurysms from other cardiac anomalies, and also prove useful to map out the coronary arteries prior to surgery.⁴ The high cost,

Table 2. Descriptive summary of cases from 2003, diagnosed using electron-beam tomography, CT angiography and CMR

Author	Age	Gender	Type	Origin	Termination	Coronary artery	Imaging	Treatment
Turkay (2003) ²²	29	M	anterior	RCS	lateral aspect of right atrium	proximal tunnel	electron beam tomography; echocardiography; angiography, intra-op images	surgery
Akar (2006) ²³	57	M	anterior	RCS	right atrium	separate	transoesophageal echocardiogram, cardiac catheterisation, CT angiogram, intra-op images	surgery
Krishna (2010) ¹³	11	F	posterior	LCS	SVC/RA junction	separate	echocardiography, cardiac catheterisation, CT angiogram, intra-op images	surgery
Walker (2010) ²⁴	25	F		NCS	right atrium		transoesophageal echocardiogram, CT angiogram	surgery
Chandra (2011) ⁸	12	F	anterior	RCS	posterior wall right atrium	separate	transoesophageal echocardiogram, CT angiogram, cardiac catheterisation	percutaneous transcatheter occlusion of tunnel
Myers (2011) ²⁵	33	M	posterior	LCS	right atrium	tunnel	cardiac catheterisation, CT angiogram, intra-op images	surgery
Sung (2011) ²⁶	73	F	anterior	RCS	right atrium	separate	CT angiogram	surgery
Salehi (2013) ¹⁸	71	M	anterior	RCS	right atrium	abutting origin of tunnel	cardiac catheterisation, transoesophageal echocardiogram, CMR	surgery
Tossios (2013) ¹²	47	F	posterior	LCS	right atrium	separate	transthoracic echocardiogram, transoesophageal echocardiogram, cardiac catheterisation, CT angiogram, CMR	surgery
Iyisoy (2014) ⁵	18	F	posterior	LCS	roof of right atrium	proximal tunnel	transoesophageal echocardiogram, cardiac catheterisation, CT angiogram	surgery
Kim (2014) ²⁷	36	F	anterior	RCS	right atrium	separate	transoesophageal echocardiogram, cardiac catheterisation, CT angiogram	surgery

CT, computed tomography; CMR, cardiac magnetic resonance; SVC, superior vena cava; RA, right atrial; RCS, right coronary sinus; LCS, left coronary sinus; NCS, non-coronary sinus

and procedure-related morbidity and mortality associated with coronary angiography have motivated the search for alternatives to this invasive procedure.²⁰

In an article published by Goldberg in 1990, CT and magnetic resonance (MR) were not widely used. It was reported to be limited by prolonged imaging time, slice thickness, radiation and cost.⁴ With the advent of 64-slice CT, cardiac CT has emerged as a useful diagnostic imaging modality for the assessment of cardiac anomalies. Imaging time has been cut down and the slices are thinner, allowing for accurate evaluation of the coronary arteries. CT angiography is now easily accessible in addition to it being non-invasive. A basic principle of radiation protection is to keep radiation exposure, 'as low as reasonably achievable' (ALARA).²¹

Tossios *et al.* were the first to image and document aorta–right atrial tunnel using cardiovascular magnetic resonance (CMR), which yielded excellent definition of the topographical anatomy of the tunnel with regard to its origin, course and termination. CMR angiography was an additional tool used to demonstrate blood flow and quantify the left-to-right shunt.¹² Therefore the combination of CMR and other modalities has improved the diagnostic precision of aorta–right atrial tunnel and has also assisted in ruling out other associated lesions, such as septal defects.¹²

Prior to 2003, most cases of ruptured sinus of Valsalva aneurysms were diagnosed using echocardiography and cardiac catheterisation. Turkay *et al.* were the first to diagnose right coronary sinus tunnel to the right atrium using electron-beam tomography.²² Tossios and Salehi were the first to diagnose aorta–right atrial tunnel using CMR.^{12,18} Table 2 shows a descriptive summary of cases from 2003, diagnosed using electron-beam tomography, CT angiography and CMR.

Conclusion

Aorta–right atrial tunnel is a rare, congenital cardiac anomaly. The diagnosis can be improved using multi-modality imaging, and with the advent of live three-dimensional echocardiography, improved CT angiography and functional CMR, detailed non-invasive imaging may be a favourable adjunct to further treatment.

References

- Thurnam J. On aneurysms and especially spontaneous varicose aneurysms of the ascending aorta and sinuses of Valsalva, with cases. *Med Chir Tr (Lond)* 1840; **23**: 323–385.
- Otero-Coto E, Cafferena JM, Such M, Marques JL. Aorta–right atrial communication: report of an unusual case. *J Thorac Cardiovasc Surg* 1980; **80**: 941–944.
- Gajjar T, Voleti C, Matta R, *et al.* Aorta–right atrial tunnel: Clinical presentation, diagnostic criteria, and surgical options. *J Thorac Cardiovasc Surg* 2005; **130**(5): 1287–1292. doi:10.1016/j.jtcvs.2005.07.021.
- Goldberg N, Krasnow N. Sinus of Valsalva aneurysms. *Clin Cardiol* 1990; **13**: 831–836.
- Iyisoy A, Celik T. Aorta–right atrial tunnel: An interesting type of a congenital coronary artery anomaly. *Korean Circ J* 2014; **44**(3): 193–195. doi:10.4070/kcj.2014.44.3.193.
- Fitton TP, Moulick A, Vricella LA. Congenital anomalies of the sinuses of valsalva and aortico-left atrial tunnel. In: Yuh, D, Vricella L, Yang S, Doty JR (eds). *John Hopkins Textbook of Cardiothoracic Surgery*. 2nd edn. New York: McGrawhill Education Medical, 2014.
- Galicia-Tornell MM, Marin-Solis B, Mercado-Astorga O, *et al.* Sinus of Valsava aneurysm with rupture. Case report and literature review. *Cir Ciruj* 2009; **77**: 441–445.
- Chandra S Vijay S, Kaur D, *et al.* Congenital aorta right atrial fistula: successful transcatheter closure with the Amplatzer occluder. *Pediatr Cardiol* 2011; **32**(7): 1057–1059.
- Sakakibara S, Konno, S. Congenital aneurysms of the sinus of Valsalva: A clinical study. *Am Heart J* 1962; **63**: 708–719.
- Levy MJ, Schachner A, Biciden LC. Aortico-left ventricular tunnel. Collective review. *J Cardiovasc Surg* 1982; **84**: 102–109.
- Bove KE, Schwartz DC. Aortico-left ventricular tunnel. *Am J Cardiol* 1967; **19**: 696–709.
- Tossios P, Sarlis G, Aidonidis G, *et al.* Aorta-right atrial tunnel: imaging and surgical repair in an adult patient. *J Cardiothorac Vasc Anesth* 2014; **28**(5): 1314–1318 doi: 10.1053/j.jvca.2013.03.025.
- Krishna CS, Baruah DK, Reddy GV. Aorta-right atrial tunnel. *Texas Heart Inst J* 2010; **37**(4): 480–482.
- Xing-biao QIU, Hong-yu SHI, Lan LIU, *et al.* Multiple aortico-cameral tunnels associated with bicuspid aortic valve in aged: a case report. *Chin Med J* 2009; **122**(18): 2184–2185. doi: 10.3760/cma.j.issn.0366-6999.2009.18.021.
- Mahesh K, Francis E, Kumar RK. Aorta to right trial tunnel. *J Am Coll Cardiol* 2008; **1**(6): 716–717 doi:10.1016/j.jcin.2008.05.011.
- Venning GR. Aneurysms of the sinuses of Valsalva. *Am Heart J* 1951; **42**: 57–63.
- Lee S, Lin T, Su H, *et al.* Ruptured aneurysm of the sinus of Valsalva into the right atrium without ventricular septal defect: a case report and literature review. *Kaohsiung J Med Sci* 2005; **21**(11): 517–521.
- Salehi A, Cui WW. Aorta–right atrial tunnel in an elderly patient. *Cardiovasc Anesthesiol: Echo Rounds* 2013; **117**(6): 1282–1285. doi: 10.1023/ANE.0b013e3182a7479.
- Hung J, Lang R, Flachskampf F, Shernan SK, McCulloch ML, Adams DB, *et al.* 3D echocardiography: A review of the current status and future directions. *J Am Soc Echocardiogr* 2007; **20**: 213–233.
- Burrill J, Dabbagh Z, Gollub F, Hamady M. Multidetector computed tomographic angiography of the cardiovascular system. *Postgrad Med J* 2007; **83**: 698–704. doi 10.1136/pgmj.2007.061804.
- Hausleiter J, Meyer T, Herman, *et al.* Estimated radiation dose associated with cardiac CT angiography. *J Am Med Assoc* 2009; **301**(5): 500–507.
- Türkay C, Gölbası I, Belgi A, *et al.* Aorta–right atrial tunnel. *J Thorac Cardiovasc Surg* 2003; **125**(5): 1058–1060. doi:10.1067/mtc.2003.87.
- Akar AR, Sirlak M. Aortico-cameral communication form right sinus of Valsalva to right atrium. *Ankara Üniversitesi Tıp Fakültesi Mecmuası* 2006; **59**(2): 73–76.
- Walker J, Lee J. Congenital aorta to right atrial fistula. *Cardiol J* 2010; **17**(5): 523–524.
- Myers PO, Milas F, Panos A. Multimodality imaging in the evaluation of aorta–right atrial tunnel. *Eur J Cardio-thorac Surg* 2011; **40**(4): 153. doi: 10.1016/j.ejcts.2011.05.044.
- Sung YM, Merchant N. Imaging of congenital aorta–right atrial tunnel with electrocardiogram gated 64-multi-slice computer tomography. *Ann Thorac Surg* 2011; **92**: 743. doi:10.1016/j.athoracsurg.2011.01.002.
- Kim KW, KIM JH, Choe WJ. Aorta–right atrial tunnel. *Eur Heart J Cardiovasc Imag* 2013; **15**(1): 112. doi:10.1093/ehjci/jet104 (accessed 01/08/2014).